

Long-term survival of stage Ib lung adenocarcinoma with postoperative brain oligometastasis: a case report and literature review

Kai Xu¹, Xing Feng², Limin Wang¹, Quan Du³, Er Jin¹

¹Department of Respiratory Medicine, Affiliated Hangzhou First People's Hospital, Zhejiang University School of Medicine, Hangzhou City, Zhejiang Province, China, ²Department of Thoracic Surgery, Affiliated Hangzhou First People's Hospital, Zhejiang University School of Medicine, Hangzhou City, Zhejiang Province, China, ³Department of Brain Surgery, Affiliated Hangzhou First People's Hospital, Zhejiang University School of Medicine, Hangzhou City, Zhejiang Province, China

Folia Neuropathol 2024; 62 (1): 108-112

DOI: <https://doi.org/10.5114/fn.2023.131120>

Abstract

Lung adenocarcinoma remains one of the most frequent and deadly tumour entities. Early-stage lung adenocarcinoma is extremely difficult to detect and is also easy to recur or metastasize after treatment. Since the new adenocarcinoma classification was presented in 2011, several studies have shown that patients with solid and/or micropapillary (S/MP) predominant patterns showed a worse prognosis. Here we report the case of a 54-year-old woman who was diagnosed with stage Ib lung adenocarcinoma with S/MP components and developed an isolated brain oligometastasis after resection and adjuvant therapy. A craniocerebral operation was performed, combined with radiotherapy and targeted therapy, and the patient eventually achieved a good quality of life. Our work reviews the clinical features of lung cancer complicated with S/MP components, the relationship between MP and epidermal growth factor receptor (EGFR) mutation, as well as treatment strategies for such a patient with postoperative brain oligometastasis of lung adenocarcinoma complicated with EGFR Exon19del mutation.

Key words: stage Ib lung adenocarcinoma, EGFR mutation, brain oligometastasis, micropapillary and solid.

Introduction

Nowadays, the morbidity and mortality of lung cancer are still high worldwide, and only a few people are lucky enough to find early lung cancer nodules during physical examination. Early-stage lung cancer, including stage I, stage II, and certain stage IIIa can be completely removed. Among them, the 5-year survival rate of stage Ib lung cancer patients was 54%, significantly lower than that of stage Ia (73%), and similar to that of stage IIa (50%) [8]. Surgery remains the cornerstone of treatment, which can effectively

improve the prognosis of such patients combined with postoperative adjuvant therapy. Herein, we introduce a female patient with stage Ib, epidermal growth factor receptor (EGFR) mutation-positive lung adenocarcinoma. She underwent radical surgery in 2017 but developed a rare brain oligometastasis without recurrent lung lesions 12.5 months later. After re-resection, radiotherapy, and targeted treatment, the patient achieved high-quality long-term survival and there has been follow-up for nearly 5 years to stabilize the disease.

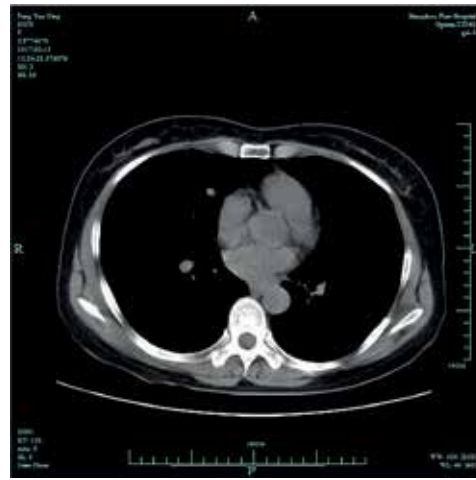
Communicating author:

Er Jin, Department of Respiratory Medicine, Affiliated Hangzhou First People's Hospital, Zhejiang University School of Medicine, No. 261 Huansha Road, Hangzhou City, Zhejiang Province, 310006, China, phone: 13958086962, e-mail: amyier@163.com

Received: 14.07.2022, Accepted: 31.05.2023, Online publication: 08.09.2023

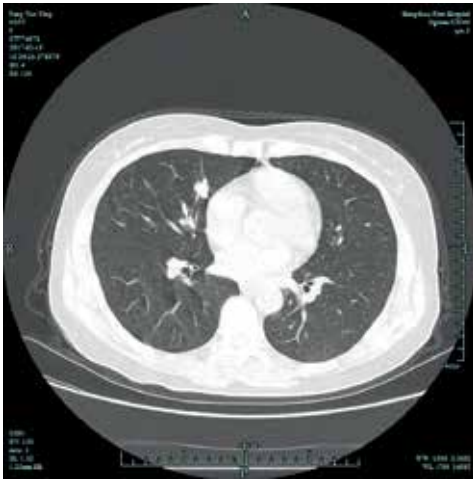

Fig. 1. Results of chest CT at the initial diagnosis.



Case presentation

The patient was a non-smoking 54-year-old woman with no past illness, who was admitted to our hospital on 20 February 2017, suspected of lung cancer. There were no obvious positive signs on the physical examination, but her chest computed tomography (CT) indicated a space-occupying lesion in the right middle lobe (Fig. 1). Relevant examinations were perfected after admission: carcinoembryonic antigen (CEA) 5.04 µg/l, brain magnetic resonance imaging (MRI) showed multiple lacunar cerebral infarcts and left occipital lobar malacia (Fig. 2). Fiberoptic bronchoscopy, upper abdominal B-ultrasound, bone emission computed tomography (ECT) and the rest of the laboratory test results showed no abnormality.

Then we conducted a comprehensive evaluation of the patient's surgical contraindications. According to the latest guidelines for primary lung cancer, contraindications to surgery mainly include: disease stage beyond the surgical criteria, extremely poor systemic condition, failure of vital organ function to tolerate surgery, or older patients requiring pneumonectomy [4]. After that, the patient underwent thoracoscopic right middle lung resection and lymph node dissection on 27 February 2017. The complete pathological results showed (Fig. 3): invasive adenocarcinoma of the right middle lobe, mainly acinar type and papillary type with solid and micropapillary components, tumour size 1.5 cm × 0.9 cm × 0.7 cm, involving one side of the lung membrane. The bronchial resection margin was not involved, and there was no metastasis in the surrounding lymph nodes. Immunohistochemistry: thyroid transcription factor-1 (TTF1)+, NapsinA+, cytokeratin 7 (CK7)+, CK20 focal+, Ki-67 10%+, anaplastic lymphoma kinase (ALK)-. Genetic testing: EGFR exon 19 deletion

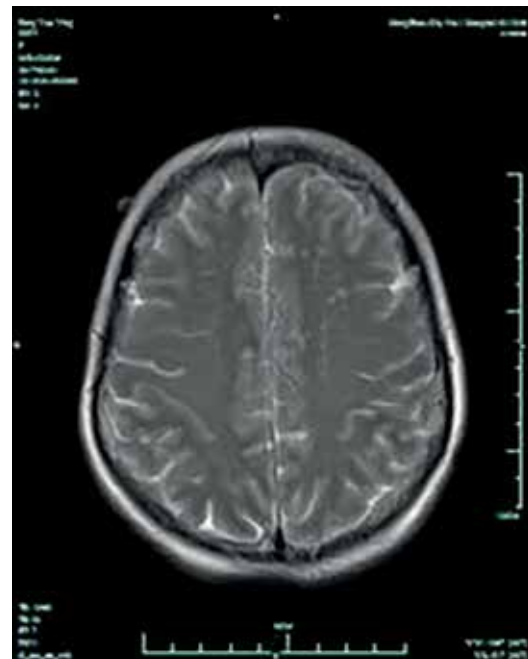


Fig. 2. Magnetic resonance imaging result at the initial diagnosis.

was positive, and ALK gene and ROS1 gene fusion were negative. The diagnosis was completed as right middle lobe invasive lung adenocarcinoma (T2aN0M0, stage Ib). Then the patient received 4 cycles of standard platinum-based adjuvant chemotherapy (pemetrexed 500 mg/m² d1 + cisplatin 35 mg/m² d1-d2).

On 14 March 2018, after a stable period of 12.5 months, the patient's brain MRI revealed a cystic lesion in the left frontal lobe (Fig. 4), while her chest CT showed no tumour recurrence. It was considered

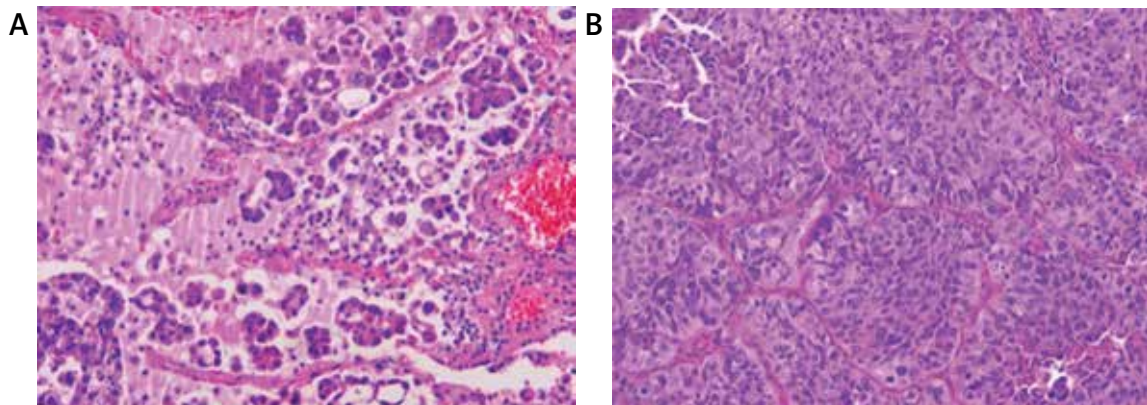


Fig. 3. Micropapillary (A) and solid (B) components of the primary tumour (H&E, 400×).

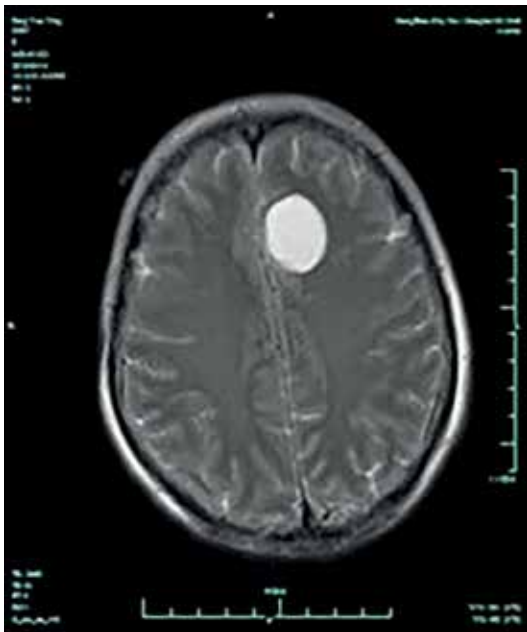

Fig. 4. Postoperative brain metastasis.

a brain metastasis from lung cancer and she was readmitted to our hospital. Left frontal lobe tumour resection was performed on 20 March 2018. Pathology showed: metastatic adenocarcinoma. Immunohistochemistry: CK+, CK7+, CK20-, TTF1+, NapsinA focal+. EGFR gene detection in brain metastases tissue showed: EGFR gene exon 19 deletion. It was confirmed as a brain oligometastasis of lung cancer (T2aNOM1b, stage IV). Then the patient received postoperative radiotherapy to the tumour bed of brain metastasis (DT: 15 GY/1 F), and gefitinib 0.25 g once a day sequentially. Her condition is stable, and she has no obvious drug side effects during the follow-up period. Moreover, the patient has not suffered from any relapse until now.

Discussion

The special features of this case are as follows: First, this patient developed a postoperative brain oligometastasis with no recurrence in the primary site. Postoperative brain metastases (BMs) for early-stage lung adenocarcinoma are quite rare. According to the study by Sakamoto *et al.* [15], about 6.7% (65/967) of lung cancer patients developed BMs after surgery, while only 3.2% (31/967) developed solitary BMs. We believe that the cause is mainly related to the S/MP components of the tumour. As two subtypes of adenocarcinoma, S/MP types have received increasing attention in recent years, often representing more aggressive tumours and poorer prognosis [17,19,20]. A Japanese study reported that the 5-year disease-free survival (DFS) of subtypes of adenocarcinomas in Japanese patients (acinar, papillary, solid, and micropapillary types) were 69.7%, 66.7%, 43.3%, and 0%, respectively [21]. Choi *et al.* and Qian *et al.* [5,14] studied patients with stage Ia or Ib-predominant lung cancer with S/MP components, respectively, and came to similar conclusions: regardless of whether the S/MP structure predominated, it is more likely to lead to postoperative recurrence or distant metastasis, and of course, worse prognosis. A recent study also pointed out that in stage I patients, the micropapillary component is associated with a higher rate of local recurrence, while the solid component is related to distant metastasis and multi-site recurrence, which peaked earlier, mostly occurring within 2 years after surgery [17]. The pathological results of this patient clearly showed the presence of S/MP components, which may be the main reason for the postoperative brain oligometastasis.

EGFR is the most common driver oncogene in non-small cell lung cancer (NSCLC), especially in Asian patients [6,16]. Moreover, micropapillary components are also associated with EGFR mutations. A Japanese study

showed that EGFR mutations are present in about 40.1% of micropapillary subtypes [10]. A recent Chinese study also observed the presence of EGFR (85.7%), human epidermal growth factor receptor 2 (HER2, 4.8%), or RET (4.8%) driver mutations in most micropapillary-predominant lung adenocarcinomas, indicating that the micropapillary type is more prone to EGFR mutations than other subtypes [22]. A previous study has demonstrated that the frequency of micropapillary patterns is higher in patients with EGFR mutations [3]. One research established the correlation between EGFR mutation status and the incidence of BMs in patients with NSCLC and showed that patients with EGFR mutations were more susceptible to developing into BMs than those with EGFR wild type [11]. In our case, the tumour had micropapillary components along with EGFR mutations, which may be the main cause of postoperative brain metastasis in this patient and provide guidance for later treatment.

After primary surgery, adjuvant therapy mainly included chemotherapy and EGFR-targeted therapy. Adjuvant chemotherapy can benefit the survival of patients with stage Ib micropapillary lung cancer [14]. The Lung Adjuvant Cisplatin Evaluation (LACE) study also confirmed that cisplatin-based chemotherapy after surgery can significantly improve the survival rate of patients [12]. This patient's tumour involved the pulmonary membrane, and her surgical procedure was wedge resection. Hence, she was a high-risk patient, for which she received four cycles of standard platinum-based adjuvant chemotherapy. At that time, major guidelines and expert consensus did not point out that tyrosine kinase inhibitor (TKI) can be used for resected early-stage lung cancer, and National Comprehensive Cancer Network (NCCN) only recommended adjuvant chemotherapy for patients with high-risk factors [13]. But at present, adjuvant targeted therapy has been considered a standard modality of cure after surgery in early-stage NSCLC [7], and there may be a better choice for this case.

After a stable period (12.5 months), brain MRI revealed cystic lesions in the left frontal lobe, and no tumour recurrence appeared on chest CT. Thus, brain metastasis was diagnosed. After the second operation, there was also a sensitive EGFR mutation in the excised tissue gene detection, suggesting that it was a brain oligometastasis of lung cancer (T2aNOM1b, stage IV). It was reported that 40% of patients develop brain metastases (BM) during the disease and NSCLC patients with EGFR mutation were more susceptible to BM than those with wildtype tumours [11]. A meta-analysis showed that TKI combined with brain radiotherapy in the treatment of EGFR-sensitive mutant NSCLC patients with BMs has better median progres-

sion-free survival (mPFS) and median overall survival (mOS) than a single drug [18]. In terms of radiotherapy, a paper in 2017 compared thoracic stereotactic body radiotherapy (SBRT) and whole-brain radiation therapy (WBRT) for resected brain metastases [2]. It was found that there is no significant difference in OS between these two, but the cognitive function and quality of life of patients who received SBRT improve. This patient developed a single cystic BM with a diameter of less than 3 cm, and her general condition was stable, so the postoperative SBRT followed by sequential gefitinib was selected for her.

In conclusion, the tumour of this patient was only less than 2 cm, but there were both S/MP components. The primary tumour invaded the lung membrane, and BM occurred after surgery, all of which are associated with poor prognosis. Some data show that the 5-year OS rate of lung cancer patients with brain metastases is only 15% [9], but this patient still achieved long-term high-quality survival, almost close to a clinical cure. We believe its EGFR sensitive mutation played a crucial role. Bae *et al.* [1] specifically studied the factors affecting the prognosis of patients with BMs after surgery and concluded that adenocarcinoma, long DFS, systemic chemotherapy, local surgery, and SBRT are all positive factors for survival after recurrence. This case almost meets all the above conditions and is a very successful case of treatment that underlines the significance of investigating adjuvant therapeutic strategies for these patients.

Funding

This study was supported in part by grants from Zhejiang Province Nature Science Funding Commission Social Development Project (grant LY19H160031); Zhejiang Provincial Medical and Health Technology Project (grant 2019KY126); and Science and Technology Development Project of Hangzhou (grant 20201231Y023).

Disclosure

The authors report no conflict of interest.

References

1. Bae MK, Yu WS, Byun GE, Lee CY, Lee JG, Kim DJ, Chung KY. Prognostic factors for cases with no extracranial metastasis in whom brain metastasis is detected after resection of non-small cell lung cancer. *Lung Cancer* 2015; 88: 195-200.
2. Brown PD, Ballman KV, Cerhan JH, Anderson SK, Carrero XW, Whitton AC, Greenspoon J, Parney IF, Laack NNI, Ashman JB, Bahary JP, Hadjipanayis CG, Urbanic JJ, Barker FG, 2nd, Farace E, Khuntia D, Giannini C, Buckner JC, Galanis E, Roberge D. Postoperative stereotactic radiosurgery compared with whole brain radiotherapy for resected metastatic brain disease (NCCTG

- N107C/CEC.3): a multicentre, randomised, controlled, phase 3 trial. *Lancet Oncol* 2017; 18: 1049-1060.
3. Chao L, Yi-Sheng H, Yu C, Li-Xu Y, Xin-Lan L, Dong-Lan L, Jie C, Yi-Lon W, Hui LY. Relevance of EGFR mutation with micropapillary pattern according to the novel IASLC/ATS/ERS lung adenocarcinoma classification and correlation with prognosis in Chinese patients. *Lung Cancer* 2014; 86: 164-169.
 4. China General Office of the National Health Commission. Clinical practice guideline for primary lung cancer (2022 Version). *Medical Journal of Peking Union Medical College Hospital* 2022; 13: 549-570.
 5. Choi SH, Jeong JY, Lee SY, Shin KM, Jeong SY, Park TI, Do YW, Lee EB, Seok Y, Lee WK, Park JE, Park S, Lee YH, Seo H, Yoo SS, Lee J, Cha SI, Kim CH, Park JY. Clinical implication of minimal presence of solid or micropapillary subtype in early-stage lung adenocarcinoma. *Thorac Cancer* 2021; 12: 235-244.
 6. Douillard JY, Ostoros G, Cobo M, Ciuleanu T, McCormack R, Webster A, Milenkova T. First-line gefitinib in Caucasian EGFR mutation-positive NSCLC patients: a phase-IV, open-label, single-arm study. *Br J Cancer* 2014; 110: 55-62.
 7. Ettinger DS, Wood DE, Aisner DL, Akerley W, Bauman JR, Bharat A, Bruno DS, Chang JY, Chirieac LR, D'Amico TA, DeCamp M, Dilling TJ, Dowell J, Gettinger S, Grotz TE, Gubens MA, Hegde A, Lackner RP, Lanuti M, Lin J, Loo BW, Lovly CM, Maldonado F, Massarelli E, Morgensztern D, Ng T, Otterson GA, Pacheco JM, Patel SP, Riely GJ, Riess J, Schild SE, Shapiro TA, Singh AP, Stevenson J, Tam A, Tanvetyanon T, Yanagawa J, Yang SC, Yau E, Gregory K, Hughes M. Non-small cell lung cancer, Version 3.2022, NCCN Clinical Practice Guidelines in Oncology. *J Natl Compr Canc Netw* 2022; 20: 497-530.
 8. Goldstraw P, Chansky K, Crowley J, Rami-Porta R, Asamura H, Eberhardt WE, Nicholson AG, Groome P, Mitchell A, Bolejack V, International Association for the Study of Lung Cancer Staging and Prognostic Factors Committee, Advisory Boards, and Participating Institutions; International Association for the Study of Lung Cancer Staging and Prognostic Factors Committee Advisory Boards and Participating Institutions. The IASLC Lung Cancer Staging Project: Proposals for revision of the TNM stage groupings in the forthcoming (eighth) edition of the TNM Classification for Lung Cancer. *J Thorac Oncol* 2016; 11: 39-51.
 9. Iyengar P, Lau S, Donington JS, Suh RD. Local therapy for limited metastatic non-small cell lung cancer: What are the options and is there a benefit? *Am Soc Clin Oncol Educ Book* 2016; 35: e460-467.
 10. Kishi N, Ito M, Miyata Y, Kanai A, Handa Y, Tsutani Y, Kushitani K, Takeshima Y, Okada M. Intense expression of EGFR L858R characterizes the micropapillary component and L858R is associated with the risk of recurrence in pNOMO lung adenocarcinoma with the micropapillary component. *Ann Surg Oncol* 2020; 27: 945-955.
 11. Li L, Luo S, Lin H, Yang H, Chen H, Liao Z, Lin W, Zheng W, Xie X. Correlation between EGFR mutation status and the incidence of brain metastases in patients with non-small cell lung cancer. *J Thorac Dis* 2017; 9: 2510-2520.
 12. Nagasaka M, Gadgeel SM. Role of chemotherapy and targeted therapy in early-stage non-small cell lung cancer. *Expert Rev Anticancer Ther* 2018; 18: 63-70.
 13. National Comprehensive Cancer Network. Non-small cell lung cancer, Version 4.2017, NCCN Clinical Practice Guidelines in Oncology. 2017.
 14. Qian F, Yang W, Wang R, Xu J, Wang S, Zhang Y, Jin B, Yu K, Han B. Prognostic significance and adjuvant chemotherapy survival benefits of a solid or micropapillary pattern in patients with resected stage IB lung adenocarcinoma. *J Thorac Cardiovasc Surg* 2018; 155: 1227-1235.e1222.
 15. Sakamoto J, Sonobe M, Kobayashi M, Ishikawa M, Kikuchi R, Nakajima D, Yamada T, Nakayama E, Takahashi T, Sato T, Chen F, Bando T, Date H. Prognostic factors for patients in postoperative brain metastases from surgically resected non-small cell lung cancer. *Int J Clin Oncol* 2014; 19: 50-56.
 16. Shi Y, Au JS, Thongprasert S, Srinivasan S, Tsai CM, Khoa MT, Heeroma K, Itoh Y, Cornelio G, Yang PC. A prospective, molecular epidemiology study of EGFR mutations in Asian patients with advanced non-small-cell lung cancer of adenocarcinoma histology (PIONEER). *J Thorac Oncol* 2014; 9: 154-162.
 17. Ujjie H, Kadota K, Chaft JE, Buitrago D, Sima CS, Lee MC, Huang J, Travis WD, Rizk NP, Rudin CM, Jones DR, Adusumilli PS. Solid predominant histologic subtype in resected stage I lung adenocarcinoma is an independent predictor of early, extrathoracic, multisite recurrence and of poor postrecurrence survival. *J Clin Oncol* 2015; 33: 2877-2884.
 18. Wang C, Lu X, Lyu Z, Bi N, Wang L. Comparison of up-front radiotherapy and TKI with TKI alone for NSCLC with brain metastases and EGFR mutation: A meta-analysis. *Lung Cancer* 2018; 122: 94-99.
 19. Yanagawa N, Shiono S, Abiko M, Katahira M, Osakabe M, Ogata SY. The clinical impact of solid and micropapillary patterns in resected lung adenocarcinoma. *J Thorac Oncol* 2016; 11: 1976-1983.
 20. Yoshizawa A, Motoi N, Riely GJ, Sima CS, Gerald WL, Kris MG, Park BJ, Rusch VW, Travis WD. Impact of proposed IASLC/ATS/ERS classification of lung adenocarcinoma: prognostic subgroups and implications for further revision of staging based on analysis of 514 stage I cases. *Mod Pathol* 2011; 24: 653-664.
 21. Yoshizawa A, Sumiyoshi S, Sonobe M, Kobayashi M, Fujimoto M, Kawakami F, Tsuruyama T, Travis WD, Date H, Haga H. Validation of the IASLC/ATS/ERS lung adenocarcinoma classification for prognosis and association with EGFR and KRAS gene mutations: analysis of 440 Japanese patients. *J Thorac Oncol* 2013; 8: 52-61.
 22. Zhang Y, Wang R, Cai D, Li Y, Pan Y, Hu H, Wang L, Li H, Ye T, Luo X, Zhang Y, Li B, Shen L, Sun Y, Chen H. A comprehensive investigation of molecular features and prognosis of lung adenocarcinoma with micropapillary component. *J Thorac Oncol* 2014; 9: 1772-1778.